



PATIENT PRESENTING CLINICAL SIGNS

Gizmo Jasuta Grade 2 HM, increased lung sounds, coughing, laryngeal paralysis, passed out- syncope? Current meds: short course of pred, low dose of lasix

SPECIES ULTRASONOGRAPHIC EXAMINATION OF THE HEART

Canine

BREED

Papillion

SEX

MN

AGE

12yr

WEIGHT

9.9lb

CANINE CARDIAC PARAMETERS	MR VMAX (m/s)	TR VMAX (m/s)	LA/AO M-mode	LA/AO (Heart Base; Swe)	FS (%)	EF (%)	EPSS (cm)
NORMAL PARAMETER	4.5-5.5	<2.7	1.3	Up to 1.6	28-40	40-100	<0.6
PATIENT	5.3	--	--	1.43	50	82	0.2
CANINE CARDIAC PARAMETERS	HR (BPM)	AV VMAX (m/s)	PV MAX (m/s)	BODY WEIGHT (kg)	LAD LA MAX 4 Chamber	LVIDd Avg; 2D and m-mode short axis (cm)	LVIDs Avg; 2D and m-mode short axis (cm)
NORMAL PARAMETER	50-100	0.7-1.7	0.7-1.6				
PATIENT	--	1.3	1.0	--	2.5	2.7	--

Cardiac Presentation

The echocardiogram in this patient demonstrated normal left atrial size based on 2 different LA measurement methods. Chamber volumes and echogenicity were normal. The cranial and caudal mitral valve leaflets presented mild thickening consistent with endocardiosis. Mild septal leaflet prolapse was present. Doppler indicated measurable moderate eccentric insufficiency. The left ventricle presented thicknesses with linear contour and was not dilated nor restricted. The myocardium presented normal echogenicity without subjective evidence of significant fibrotic or ischemic disease. Contractility of the ventricular walls was adequate and in normal range for this patient evidenced by the fractional shortening measurement and subjective evaluation of the different regions of the myocardium. The left ventricular outflow tract demonstrated normal laminar flow and subjective structural integrity. The right atrium and auricle revealed normal size, structure and content. No evidence of masses was noted or chamber overload. Tricuspid valvular assessment demonstrated adequate linear morphology. The right ventricle was of normal size (1/3 diameter of LV), chordae structure, myocardial echogenicity and thickness. Pulmonic tract assessment revealed normal valve structure, laminar flow, and diameter (approx.1:1 pa/ao ratio). No visible pericardial or free pleura fluid was noted. No echographically detectable evidence of infiltrative disease was visible. The cranial mediastinum and pericardial regions were free of masses in the visible window.

ULTRASONOGRAPHIC FINDINGS

Primary

- Chronic mitral valve disease with mild valve prolapse (B1)

INTERPRETED BY

R. McKenzie Daniel, DVM, DABVP (Canine and Feline)

IMAGING PERFORMED BY

Meghan Morse

HOSPITAL NAME

AH of Sullivan County

REFERRING VET

Dr Bodolosky

INVOICE
22318

DATE
12/22/2025



PATIENT

Gizmo Jasuta

SPECIES

Canine

BREED

Papillion

SEX

MN

AGE

12yr

WEIGHT

9.9lb

INTERPRETED BY

R. McKenzie Daniel,
 DVM, DABVP
 (Canine and Feline)

IMAGING PERFORMED BY

Meghan Morse

HOSPITAL NAME

AH of Sullivan County

REFERRING VET

Dr Bodolosky

INVOICE
 22318

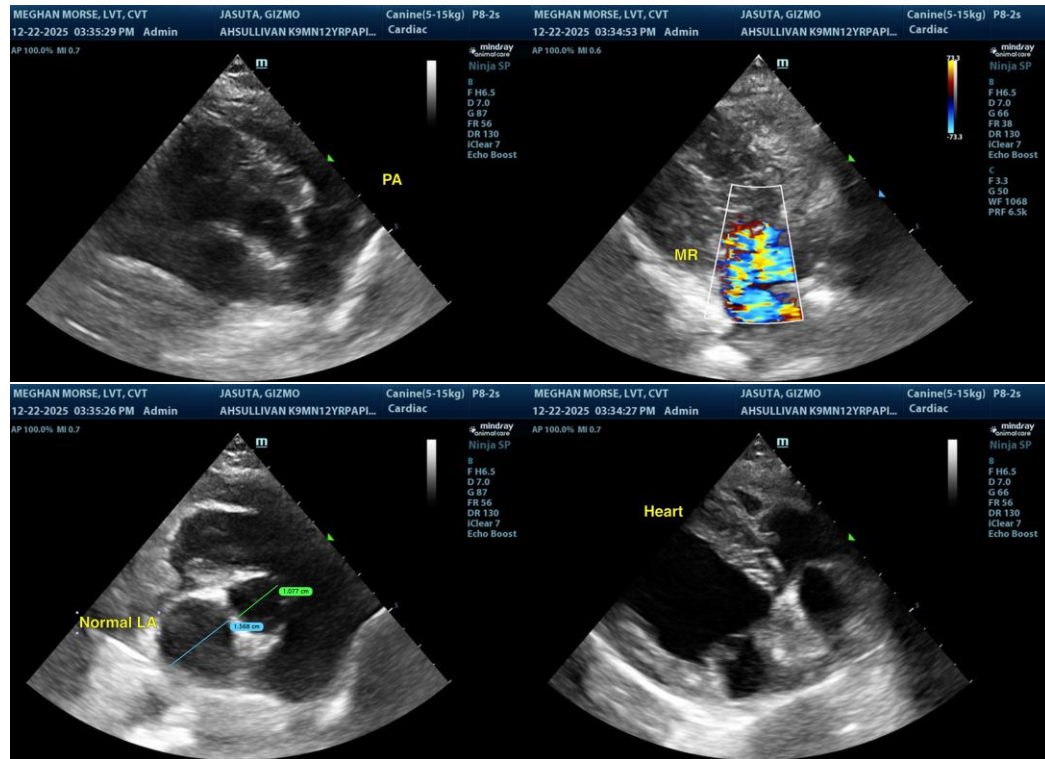
DATE
 12/22/2025

INTERPRETATION OF THE FINDINGS & FURTHER RECOMMENDATIONS

The cause of the murmur is subjective mild chronic degenerative valvular changes with secondary MR. No evidence of additional issues such as DCM criteria, LV systolic dysfunction or clinical pulmonary hypertension. The lack of left atrial enlargement implies that the risk of complication secondary to mitral valve insufficiency is relatively low at this time and, without current clinical signs, indicates that medical therapy is not required at this stage. The respiratory signs in this patient are non-cardiogenic in origin.

Prognosis at this stage is variable and serial sonographic monitoring is recommended with a recheck echocardiogram in 6 months, sooner if clinical signs suggestive of heart disease develop.

Anesthetic risk is considered mild. Suggested anesthetic protocol may include opioid or Benzodiazepine pre-med, induction with Propofol or Alfaxalone, and appropriate gas anesthesia with avoidance of alpha 2 agonists.



The information and recommendations provided are based on the images presented by the referring veterinarian/sonographer. No evaluation can be communicated regarding pathology that was not visible in the image/video clips provided.

Thank you for this referral. If the clinical or image interpretation does not parallel your findings or if I can be of any further assistance, please contact me.



PATIENT

Gizmo Jasuta

R. McKenzie Daniel, DVM, DABVP (Canine/Feline Practice)

info@sonopath.com

SPECIES

Canine

BREED

Papillion

SEX

MN

AGE

12yr

WEIGHT

9.9lb

INTERPRETED BY

R. McKenzie Daniel,
DVM, DABVP
(Canine and Feline)

**IMAGING
PERFORMED BY**

Meghan Morse

HOSPITAL NAME

AH of Sullivan County

REFERRING VET

Dr Bodolosky

**INVOICE
22318**

DATE
12/22/2025